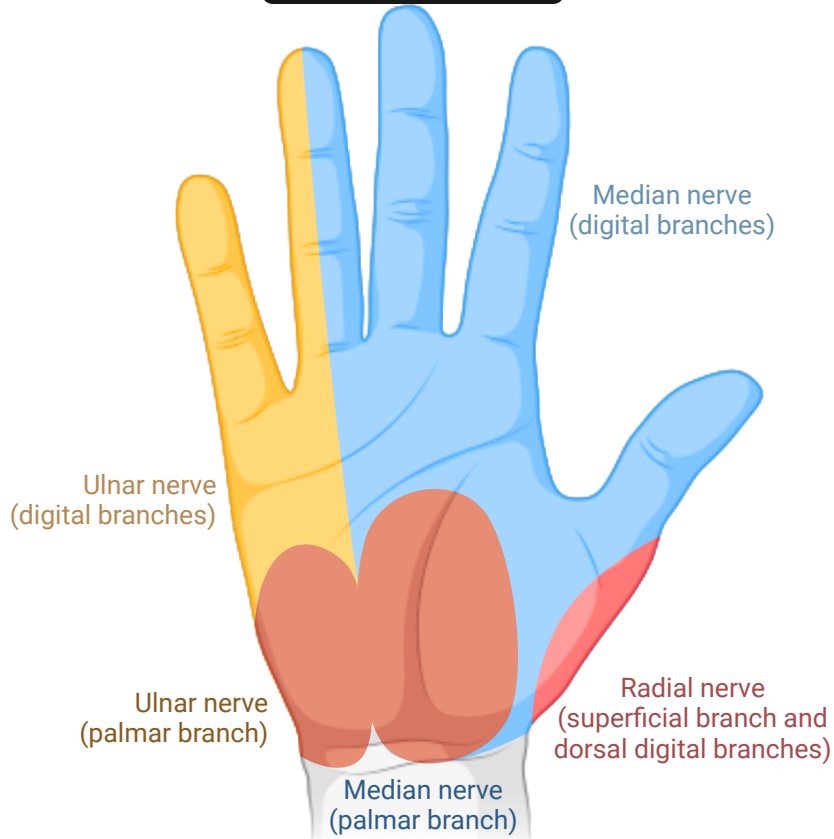


# Sensory Innervation of the Hand

**Anterior**



**Posterior**

