

Airway Axis in Relation to Position

OA - Oral axis
PA - Pharyngeal axis
LA - Laryngeal axis

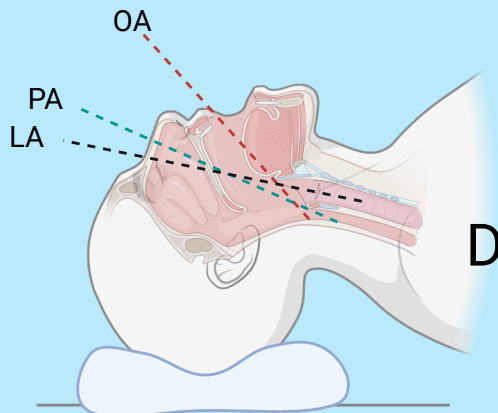
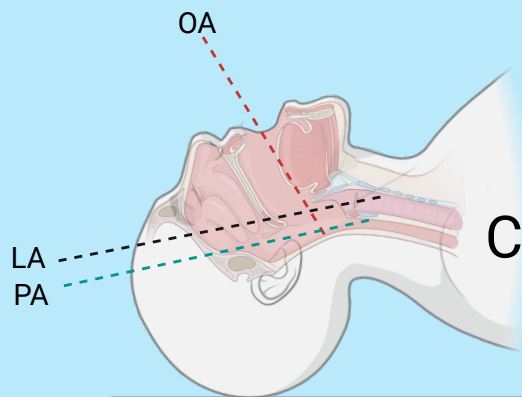
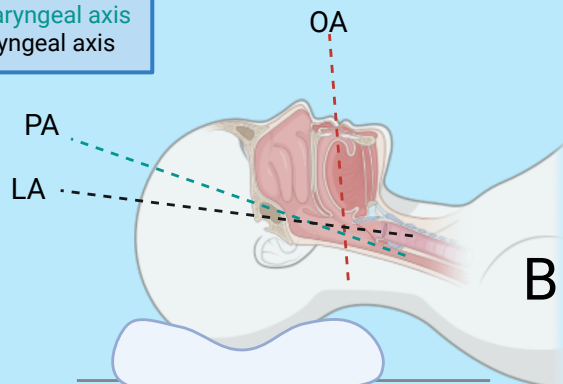
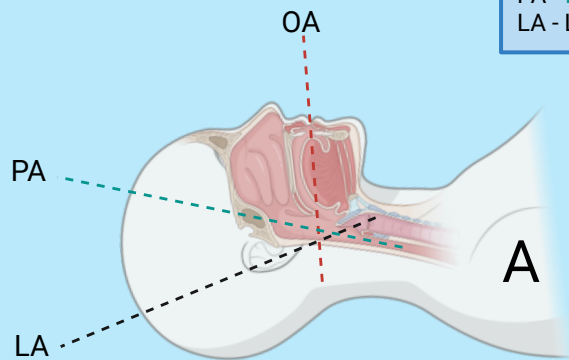


Figure A

Non-aligned normal resting position

Figure B

PA and LA are aligned by flexion of the neck caused by placing a pad beneath the patient's head

Figure C

Extension of the neck causes alignment of the PA and LA but not the OA

Figure D

Flexion of the neck caused by elevation of the patient's head onto a pad, combined with neck extension (sniffing position) best aligns the OA, PA, and LA. This position is optimal for intubation