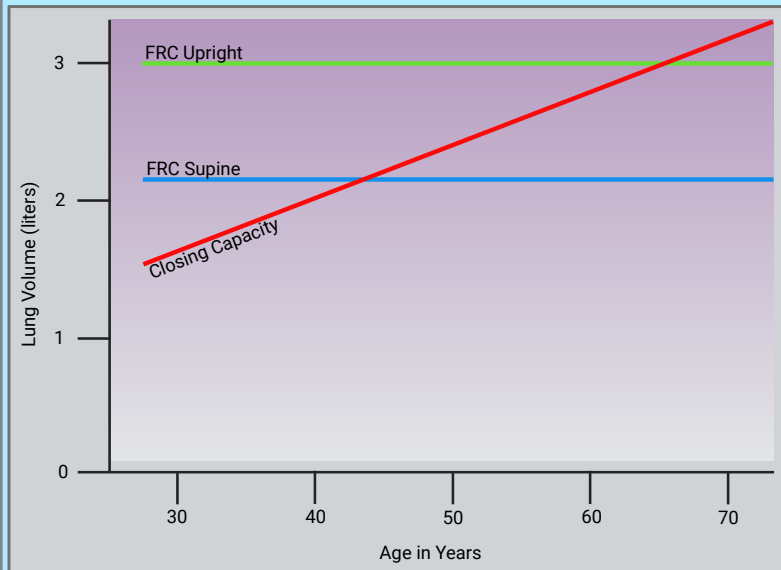


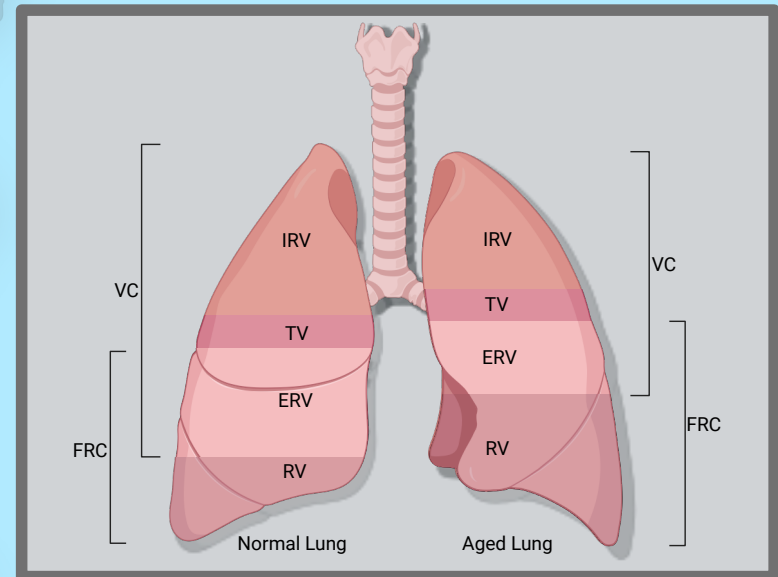
# The Aging Lung

## A Quick Look

There are many age-related changes that are seen in the respiratory system. The figures below take a quick look at non-pathologic changes that can be seen in the aging lung



Adapted from Barash Fig. 54.2, 54.3 pg. 1263



In the aged lung, note the decrease in IRV, ERV and VC. Note the increase in RV and FRC. TLC remains relatively the same.